



**PRESENTING CLINICAL SIGNS**

**DATE** History: BNP 123. Transitional epithelial cells in urine.

**7/18/23** **ECHOCARDIOGRAPHIC FINDINGS**  
2D, M-mode, and Doppler study.

**PERFORMED BY:** Left atrial size is normal. The mitral valve appears normal, though mild mitral regurgitation is present. There is mild hypertrophy of the interventricular septum. Left ventricular posterior wall thickness is normal. Left ventricular internal dimensions are normal. Left ventricular systolic function is normal. The aorta and aortic valve are normal. Right atrial and right ventricular dimensions are normal. The tricuspid valve appears normal, though trace tricuspid regurgitation is present. There is dynamic obstruction to flow in the right ventricular outflow tract. The pulmonary artery and pulmonic valve are normal. No pericardial effusion or cardiac masses are seen.

Dr. Brian Barnes

**INTERPRETED BY**

Keith Blass, DVM,  
MS, DACVIM  
(Cardiology)

ECG during echo: Sinus rhythm

**PATIENT** LA/Ao - 1.28

Charlee Everett

IVSd - 6.5 mm  
LVPWd - 5.5 mm  
LVIDd - 16.2 mm  
LVIDs - 7.8 mm  
FS - 51.8%  
LVOT - 1.20 m/s  
RVOT - 2.89 m/s

**SPECIES**

Feline

**ASSESSMENT/RECOMMENDATIONS**

**BREED**

Himalayan

Hypertrophic cardiomyopathy (HCM)

This examination demonstrates mild hypertrophy of Charlee's interventricular septum, consistent with the presence of HCM. The hemodynamic effects of the hypertrophy appear to be mild, as Charlee does not have secondary dilation of her left atrium. As such, Charlee's current risk for the development of congestive heart failure and/or thromboembolic disease appears to be fairly low, though careful monitoring for clinical signs associated with these conditions is recommended going forward.

**SEX**

FS

No therapy is recommended at this stage of disease.

**AGE**

12 y

A recheck echocardiogram is recommended in 6-9 months. Thoracic radiographs are recommended if Charlee experiences respiratory clinical signs.

**WEIGHT**

5.9 kg

**HOSPITAL NAME**

Westview VH

**REFERRING VET**

Dr. Barnes



DATE

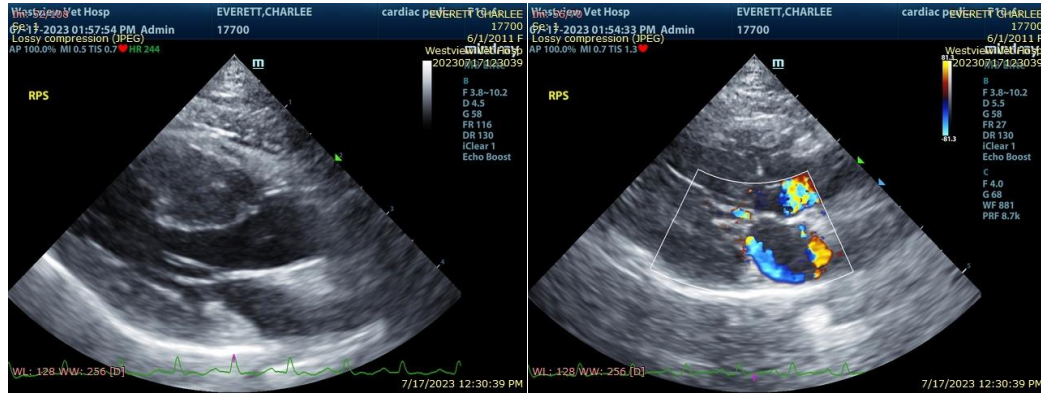
7/18/23

PERFORMED BY:

Dr. Brian Barnes

INTERPRETED BY

Keith Blass, DVM,  
MS, DACVIM  
(Cardiology)



PATIENT

Charlee Everett

The information and recommendations provided are based on the images presented by the referring veterinarian. No evaluation can be communicated regarding pathology that was not visible in the image/video clips provided.

Thank you for this referral. If the clinical or image interpretation does not parallel your findings or if I can be of any further assistance please contact me.

SPECIES

Feline

Keith Blass, DVM, MS, DACVIM (Cardiology)  
KeithBlass@gmail.com  
631-804-5754

BREED

Himalayan

SEX

FS

AGE

12 y

WEIGHT

5.9 kg

HOSPITAL NAME

Westview VH

REFERRING VET

Dr. Barnes